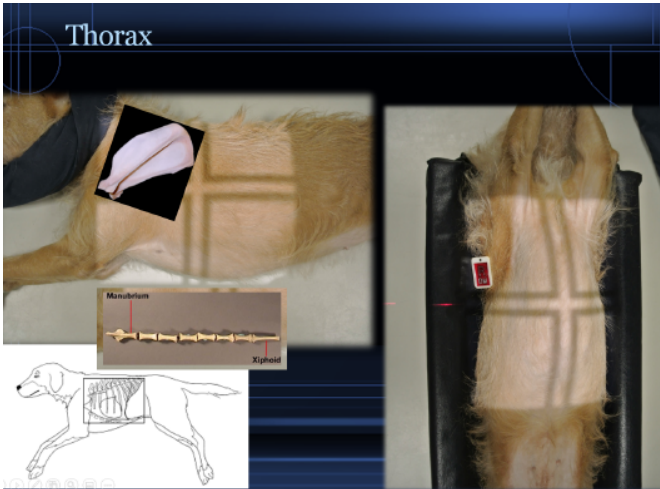




Technical Tips

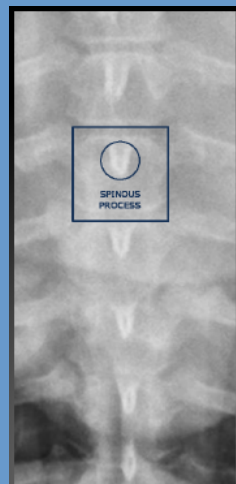
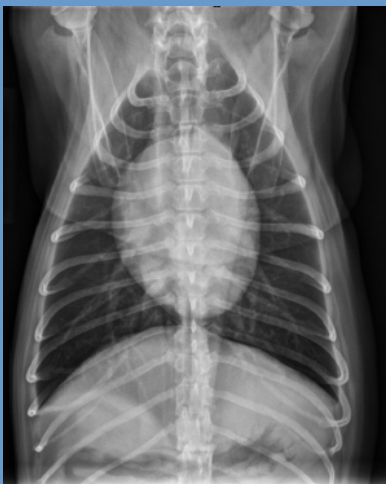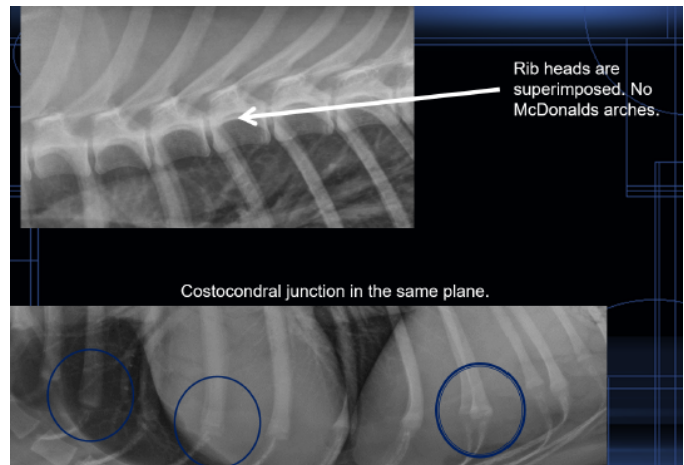
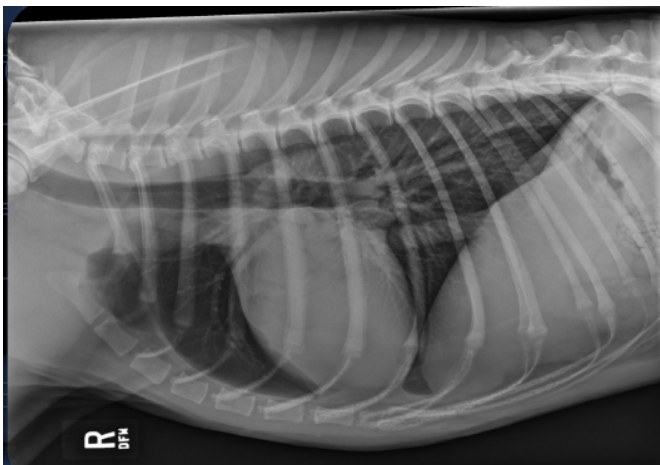
Radiography: Thorax



Include All Anatomy

Palpate Landmarks:

- Center on the heart beat
- Caudal edge of scapula
- Manubrium for lung margin
- Sternum +4 finger widths for caudal lung tips



VD or DV View

- Avoid rotation
- Center the spinous processes in the spinal column

Images courtesy of Danielle Mauragis, CVT, Radiology, University of Florida, 2015.