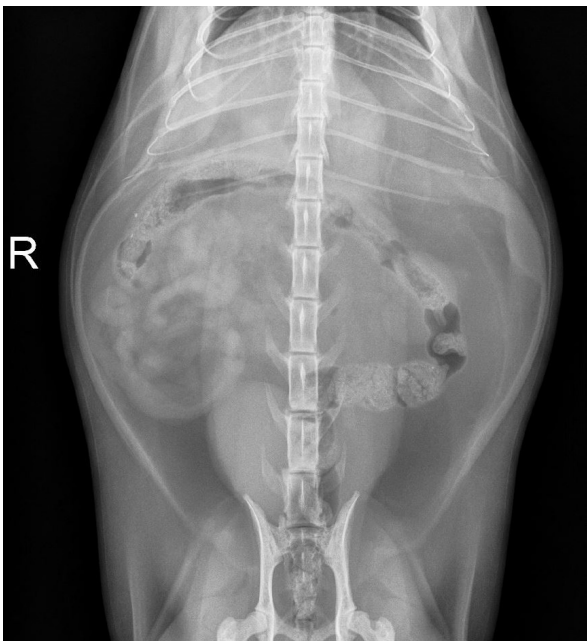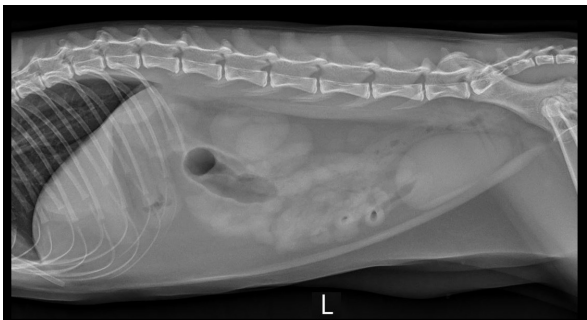
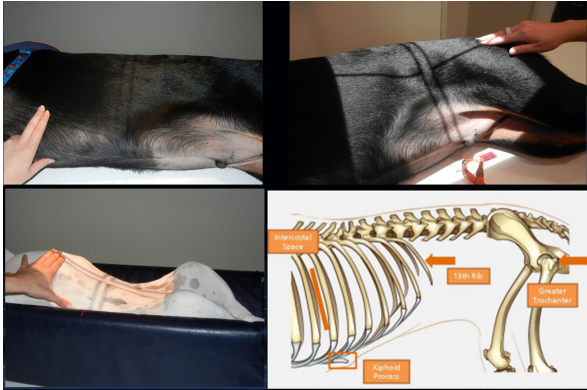




# Technical Tips

## Radiography: Abdomen



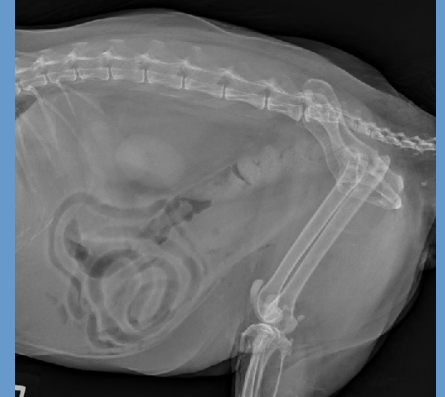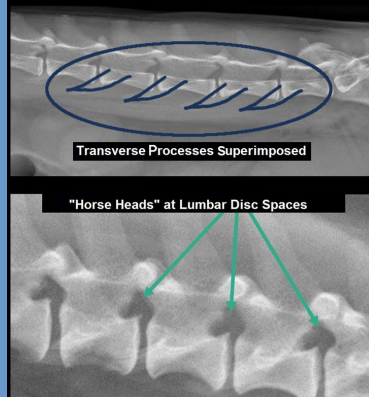
### Include All Anatomy

#### Palpate Landmarks:

- Center about 13th rib
- Xiphoid + 4 fingers cranial for entire liver
- Dorsal spinous processes and ventral sternum
- Greater trochanter of hip

#### Urinary History

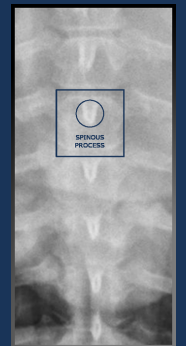
- Include all caudal soft tissue to visualize urethra
- If male, add flexed lateral view



#### VD View

- Avoid rotation
- Center the spinal column →

All Views: Take on Expiration



Images courtesy of:  
Danielle Mauragis, CVT, Radiology, University of Florida, 2015. Images 1, 4 and 6.  
MedVet (2021). Images 2, 3, and 5.